



Reliability of prenatal detection of X-linked hypohidrotic ectodermal dysplasia by tooth germ sonography

Johanna Hammersen¹ | Sigrun Wohlfart¹ | Tamme W. Goecke² | Angela Köninger³ | Holger Stepan⁴ | Ralph Gallinat⁵ | Susan Morris⁶ | Katharina Bücher⁷ | Angus Clarke^{6,8} | Stephanie Wünsche¹ | Matthias W. Beckmann¹ | Holm Schneider¹ | Florian Faschingbauer¹

¹Center for Ectodermal Dysplasias, University Hospital Erlangen, Erlangen, Germany

²Department of Gynecology and Obstetrics, RWTH Aachen, Aachen, Germany

³Department of Gynecology and Obstetrics, University of Duisburg-Essen, Essen, Germany

⁴Department of Obstetrics, University Hospital Leipzig, Leipzig, Germany

⁵Frauenärztliche Gemeinschaftspraxis Günzburg-Ichenhausen, Günzburg, Germany

⁶Cardiff and Vale University Health Board, University Hospital of Wales, Cardiff, UK

⁷Department of Conservative Dentistry and Periodontology, University Hospital, Ludwig-Maximilians University, Munich, Germany

⁸Institute of Medical Genetics, School of Medicine, Cardiff University, Cardiff, UK

Correspondence

Dr Johanna Hammersen, Department of Pediatrics, University Hospital Erlangen, Loschgestr. 15, 91054 Erlangen, Germany. Email: johanna.hammersen@uk-erlangen.de

Present Address

Dr Tamme W. Goecke is currently affiliated with the Department of Gynecology and Obstetrics, RoMed Hospital, Rosenheim, Germany.

Abstract

Objective: In X-linked hypohidrotic ectodermal dysplasia (XLHED), dysfunction of ectodysplasin A1 (EDA1) due to EDA mutations results in malformation of hair, teeth, and sweat glands. Hypohidrosis, which can cause life-threatening hyperthermia, is amenable to intrauterine therapy with recombinant EDA1. This study aimed at evaluating tooth germ sonography as a noninvasive means to identify affected fetuses in pregnant carrier women.

Methods: Sonography, performed at 10 study sites between gestational weeks 18 and 28, led to the diagnosis of XLHED if fewer than six tooth germs were detected in mandible or maxilla. The assessment was verified postnatally by EDA sequencing and/or clinical findings. Estimated fetal weights and postnatal weight gain of boys with XLHED were assessed using appropriate growth charts.

Results: In 19 of 38 sonographic examinations (23 male and 13 female fetuses), XLHED was detected prenatally. The prenatal diagnosis proved to be correct in 37 cases; one affected male fetus was missed. Specificity and positive predictive value were both 100%. Tooth counts obtained by clinical examination corresponded well with findings on panoramic radiographs. We observed no weight deficits of subjects with XLHED in utero but occasionally during infancy.

Conclusion: Tooth germ sonography is highly specific and reliable in detecting XLHED prenatally.

1 | INTRODUCTION

X-linked hypohidrotic ectodermal dysplasia (XLHED) is caused by mutations of the X-chromosomal gene ectodysplasin A (EDA) that lead to absence or dysfunction of the signaling protein EDA1 and thus to developmental defects of hair, teeth, and various eccrine glands including sweat glands.¹⁻³ Male subjects with XLHED suffer from oligodontia, hypohidrosis, or anhidrosis with very dry, often eczematous skin, dry eyes, and recurrent respiratory infections.⁴⁻⁸ Inability to sweat poses affected individuals at risk of life-threatening hyperthermia, especially in early infancy.^{4,8-10} Missing or peg-shaped teeth are also of clinical relevance,^{11,12} as they may cause mastication

problems and reduced nutritional intake. Failure to thrive has been observed in many affected boys.¹³ Mortality is high (2%-30%) and depends on the time point of diagnosis.^{4,10}

So far, treatment of XLHED has been symptomatic. New therapeutic options may arise from a recombinant EDA1 molecule, which rescued normal development in murine and canine models of XLHED.¹⁴⁻¹⁶ In order to achieve the same therapeutic effects in humans, prenatal administration of the EDA1 replacement protein appears to be required.^{17,18} Three recent case studies have shown that intraamniotic injection of recombinant EDA1 at the beginning of the third trimester of pregnancy may prevent the development of XLHED-related morbidity.¹⁸ A clinical trial to evaluate this therapeutic approach is currently being prepared. As such treatment in utero requires repeated amniocentesis, any additional invasive procedure

Holm Schneider and Florian Faschingbauer contributed equally.

during the pregnancy should be avoided. Therefore, a noninvasive method to identify affected fetuses in time for prenatal therapy is desirable.

Ultrasound is a noninvasive standard prenatal diagnostic imaging tool, which also allows depiction of fetal tooth germs.¹⁹ Tooth buds and thus oligodontia can be visualized as early as in the first trimester of pregnancy.²⁰ Tooth germ sonography or sonographic screening for facial characteristics has been used in single centers to detect XLHED prenatally.^{21,22} The aim of this retrospective multicenter study was to evaluate the accuracy of tooth germ sonography as a noninvasive method to identify fetuses with XLHED in pregnant carriers of *EDA* mutations.

2 | SUBJECTS AND METHODS

2.1 | Prenatal sonography

This retrospective study involved 10 prenatal medicine specialist sites in Germany and Great Britain. In case of pregnant women who participated in the prenatal screening program of clinical trial ECP-002 (A phase 2 open-label, dose-escalation study to evaluate the safety, pharmacokinetics, immunogenicity and pharmacodynamics/efficacy of EDI200 in male infants with X-linked hypohidrotic ectodermal dysplasia; EudraCT number 2012-003561-17), the study procedures had been approved by an independent institutional ethics committee; in all other cases, ethical approval was waived by the institutional ethics committee for retrospective studies without patient identifiers. All physicians who performed the ultrasound examinations were experts in fetal medicine and had comparable levels of experience. Before the first screening for XLHED, they had received oral instructions, 2D-ultrasound pictures, and/or videos of sonographic tooth germ evaluation providing equal levels of training. Ultrasound examinations were carried out using the standard high-end devices. A total of 33 pregnant women with known *EDA* mutations, one with a polyzygotic triplet pregnancy, one with a monozygotic twin pregnancy, and 31 with singleton pregnancies, had been referred to one of the participating sites in the years 2010 to 2017. Detailed sonography was carried out at a gestational age of 18 to 28 weeks. All women gave informed consent prior to the ultrasound scan. Two pregnant women who were willing to travel underwent independent ultrasound examinations at two different sites; observers were blinded to the previous findings so that tooth germ sonography was performed in 38 cases.

In two-dimensional axial sections of mandible and maxilla, round hypoechogenic structures arranged in an arch-like fashion in the alveolar bone were identified as tooth germs and counted; in accordance with the literature available at the beginning of our study, their number was considered to be reduced if it was below six in one of the alveolar bones.^{22,23} Additional screening for fetal malformations was performed. On the basis of the tooth germ counts, we diagnosed or excluded fetal XLHED. In a few cases, the number of tooth germs was not determined exactly because of unfavorable conditions for the examination, eg, spine-up position of the fetus but classified as “reduced” or “normal.”

All ultrasound-based diagnoses were verified by *EDA* gene sequencing ($n = 26$) and/or clinical findings including standardized assessments of hair, sweating, and dentition after birth ($n = 31$).

What is already known about this topic?

- In X-linked hypohidrotic ectodermal dysplasia (XLHED), a developmental disorder characterized by malformation of hair, teeth, and sweat glands, inability to sweat can lead to life-threatening hyperthermia. Hypohidrosis has been shown to be amenable to prenatal therapy.
- Tooth germ sonography may be used to detect fetal XLHED in pregnant carrier women but has not yet been evaluated in a broader setting.

What does this study add?

- Tooth germ sonography is highly specific and reliable in detecting or ruling out fetal XLHED in pregnant carriers.
- Such sonographic assessments can be conducted in different countries at various sites representing different levels of care.
- This noninvasive method allows recognition of XLHED in time for possible prenatal therapy or prevention of dangerous hyperthermic episodes in early infancy.

2.2 | Statistical analysis

The 95% confidence intervals (95% CIs) were calculated using the exact method of Clopper and Pearson.²⁴

2.3 | Postnatal tooth quantification

This investigation was part of the clinical study “Natural history and outcomes in X-linked hypohidrotic ectodermal dysplasia” (NCT02099552, www.clinicaltrials.gov). Parents or legal guardians provided informed consent to the study procedures, which had been approved by an independent institutional ethics committee and were conducted according to national regulations and Good Clinical Practice/International Conference on Harmonization (GCP/ICH) guidelines. Standardized clinical assessments of dentition in children were compared with panoramic dental radiographs where the number of teeth and tooth buds was determined by experienced dentists. Panoramic radiographs from the XLHED patients reported here were obtained at the age of 4 7/12 to 5 1/12 years.

2.4 | Assessment of prenatal and postnatal weight gain

On the basis of measurements of abdominal circumference, femur length, and head circumference, the body weight of 12 male fetuses with XLHED was estimated according to the formula used by default

at each site (in most cases, the formula of Hadlock et al),²⁵ Percentiles for the control population were taken from published World Health Organization (WHO) fetal growth charts.²⁶

Biometrical data obtained during routine pediatric examinations were included in the retrospective analysis of weight-for-age charts with published percentiles for the normal population.²⁷ For preterm infants, only age-corrected data were used.

3 | RESULTS

Prenatal tooth germ sonography at 10 study sites in Germany and Great Britain allowed the identification of fetuses with XLHED in 19 of 38 cases (Table 1). Most of these investigations were carried out at one site, a level III university hospital; 13 examinations were performed at the nine other sites.

TABLE 1 Study sites and experience with detecting X-linked hypohidrotic ectodermal dysplasia (XLHED) by tooth germ sonography

Label	Description of the Study Site	Number of Cases Referred for Prenatal XLHED Screening	Screening Result: Affected Male Fetus	Screening Result: Affected Female Fetus	Incorrect Prenatal Assessment
A	University hospital	25	9/15	3/10	0
B	University hospital	3	1/1	1/2	0
C	University hospital	2	2/2	-	0
D	University hospital	2	1/2	-	0
E	University hospital	1	0/1	-	0
F	Municipal hospital	1	1/1	-	0
G	Private medical center	1	1/1	-	0
H	Private medical center	1	0/1	-	1
I	Private medical center	1	-	0/1	0
J	Private medical center	1	0/1	-	0
Total		38	15/25	4/13	1

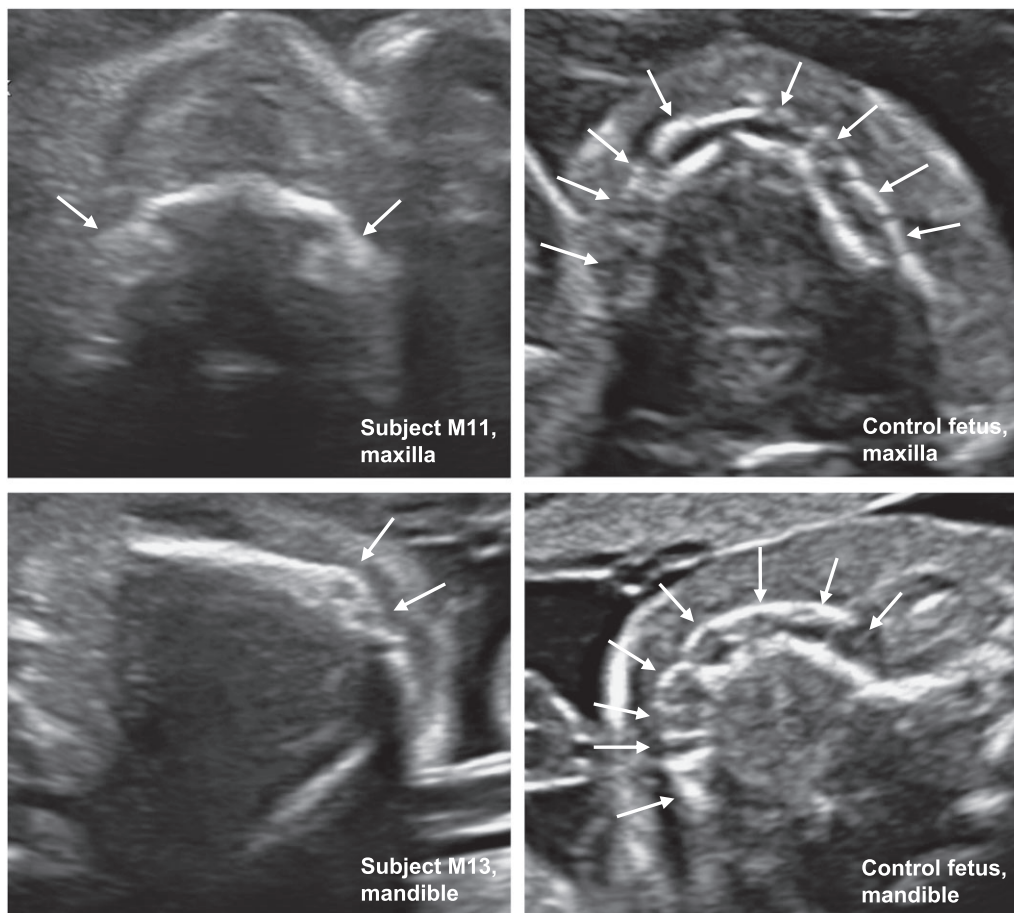


FIGURE 1 Prenatal sonographic screening for X-linked hypohidrotic ectodermal dysplasia (XLHED). In healthy controls (upper and lower right panel), axial sections of alveolar bones show a normal number of tooth germs, represented by round hypoechogenic structures that are arranged in an arch-like fashion in the alveolar bone and highlighted by white arrows. In fetuses with a reduced number of tooth germs in the maxilla (upper left panel: fetus M11 at 21 weeks of gestation) or in the mandible (lower left panel: fetus M13 at 23 weeks of gestation), XLHED was diagnosed. Lack of tooth germs was accompanied by a thin, hypoplastic alveolar bone

TABLE 2 Ultrasonographic findings in fetuses of mothers with known ectodysplasin A (EDA) mutations between 2010 and 2017

Subject	Maternal EDA Mutation	Time of Sonography (Completed Weeks of Gestation)	Ultrasonographic Assessment (Including Estimated Fetal Weight)	Number of Tooth Germs in the Mandible	Postnatal Diagnosis
M1	p.P17GfsX81	21	Male fetus, only two tooth germs detectable → XLHED, 396 g	0	XLHED
M2	p.Y304C	21	Male fetus, normal amount of tooth germs	≥6	No XLHED
M3	p.P220_P225del	21	Male fetus, clearly reduced number of tooth germs → XLHED, 432 g	0	XLHED
M4	Exon2del	20	Male fetus, normal amount of tooth germs	≥6	No XLHED
M5	p.R155C	21	Male fetus, normal amount of tooth germs	≥6	No XLHED
M6	p.R156H	20	Trichorionic triplets; reduced number of tooth germs in the male fetus → XLHED, 329 g	3	XLHED
M7	Exon2dupl	24	Male fetus, very few tooth germs detectable → XLHED, 667 g	0	XLHED
M8	p.T378 M	21	Male fetus, normal amount of tooth germs	≥6	No XLHED
M9	p.R155C	22	Male fetus, reduced number of tooth germs → XLHED, 454 g	1	XLHED
M9	p.R155C	27	Male fetus, only four tooth germs detectable → XLHED, 910 g	1	XLHED
M10	p.G291R	20	Male fetus, normal amount of tooth germs	≥6	No XLHED
M11	p.Y304C	21	Monochorionic twins, male fetus, only two tooth germs detectable → XLHED, 425 g	0	XLHED
M12	p.Y304C	21	Monochorionic twins, male fetus, only one tooth germ detectable → XLHED, 401 g	0	XLHED
M13	p.V309GfsX8	23	Male fetus, clearly reduced number of tooth germs → XLHED, 739 g	2	XLHED
M14	Exon4del	28	Male fetus, normal amount of tooth germs	n.d.	No XLHED
M15	p.G350 V	28	Male fetus, reduced number of tooth germs → XLHED	2	XLHED
M16	p.L11PfsX46	20	Male fetus, only four tooth germs detectable → XLHED, 337 g	0	XLHED
M17	p.R156H	20	Male fetus, normal amount of tooth germs	n.d.	No XLHED
M18	p.P191_P196del	19	Male fetus, normal amount of tooth germs	≥6	No XLHED
M19	p.G381R	20	Male fetus, normal amount of tooth germs	n.d.	XLHED
M20	p.G201X	20	Male fetus, clearly reduced number of tooth germs → XLHED, 362 g	1	XLHED
M21	p.C27X	18	Male fetus, normal amount of tooth germs	≥6	No XLHED
M22	p.R155C	19	Male fetus, very few tooth germs detectable → XLHED, 292 g	0	XLHED
M22	p.R155C	21	Male fetus, only two to three tooth germs detectable → XLHED, 433 g	0	XLHED
M23	c.396 + 5G > A	23	Male fetus, reduced number of tooth germs → XLHED, 571 g	2	XLHED
F1	p. R156H	20	Trichorionic triplets, female fetus, normal amount of tooth germs	≥6	No XLHED
F2	p. R156H	20	Trichorionic triplets, second female fetus, reduced number of tooth germs → XLHED	5	XLHED
F3	p.G85AfsX6	19	Female fetus, normal amount of tooth germs	n.d.	No XLHED
F4	p.P220_P225del	20	Female fetus, reduced number of tooth germs → XLHED	n.d.	XLHED
F5	p.Y304N	21	Female fetus, normal amount of tooth germs	≥6	No XLHED
F6	p.P191_P196del	19	Female fetus, normal amount of tooth germs	≥6	No XLHED

(Continues)

TABLE 2 (Continued)

Subject	Maternal EDA Mutation	Time of Sonography (Completed Weeks of Gestation)	Ultrasonographic Assessment (Including Estimated Fetal Weight)	Number of Tooth Germs in the Mandible	Postnatal Diagnosis
F7	p.D126PfsX10	20	Female fetus, normal amount of tooth germs	n.d.	No XLHED
F8	p.I371N	23	Female fetus, normal amount of tooth germs	≥6	No XLHED
F9	p.R153C	21	Female fetus, reduced number of tooth germs → XLHED	n.d.	XLHED
F10	p.T278LfsX2	21	Female fetus, normal amount of tooth germs	≥6	No XLHED
F11	p.R155C	19	Female fetus, normal amount of tooth germs	≥6	No XLHED
F12	p.I312N	20	Female fetus, normal amount of tooth germs	≥6	No XLHED
F13	Exon2del	22	Female fetus, reduced number of tooth germs → XLHED	n.d.	XLHED

Abbreviations: F, female subject; M, male subject; n.d., not exactly determined; XLHED, X-linked hypohidrotic ectodermal dysplasia. Some data on fetuses M1 to M7 and F1 to F4 were published previously.²²

A partial set of data on fetuses M1 to M7 and F1 to F4 was published previously.²² In all sonographic examinations, tooth-bearing bones were depictable in axial two-dimensional ultrasound sections, and tooth germs were evaluated in both jaws (Figure 1). Lack of tooth germs was observed more often in the mandible than in the maxilla. In eight male fetuses, tooth buds were completely absent in the lower jaw (Table 2). A reduced number of tooth germs were typically accompanied by a thin, hypoplastic alveolar bone (Figure 1). Ten male and nine female fetuses were considered as not affected (Table 2). Molecular genetic investigations and/or postnatal clinical examinations of dentition (Figure 2) confirmed the ultrasound-based diagnosis in 37 of 38 cases. In one subject, the prenatal assessment proved to be wrong: a male fetus with sonographically normal appearance of tooth germs was considered as not affected, but XLHED was diagnosed postnatally (Table 2).

In total, 19 of 20 XLHED subjects were identified prenatally by tooth germ sonography (sensitivity of 95.0%; 95% CI, 75.1-99.9). There was no false positive result, so that specificity and positive predictive value of prenatal detection of XLHED by tooth germ sonography were both 100% (95% CI, 81.5-100 and 82.4-100, respectively). The ultrasound-based prenatal diagnosis "not affected subject" proved to be right in 18 of 19 cases; the negative predictive value was 94.7% (95% CI, 74.0-99.9). Overall, the prenatal assessments were correct in 97.4% of cases (95% CI, 86.2-99.9) (Tables 1 and 2).

Wherever possible, prenatal and postnatal assessments of tooth endowment in individual subjects were compared. They usually corresponded well. In patient M6, for example, five tooth germs had been identified in the maxilla prenatally; four deciduous and two permanent teeth were detected radiographically at an age of 4 years (Figure 3). The three tooth germs counted in the mandible of that patient in utero were confirmed to be three teeth later in the panoramic radiograph (Figure 3, Table 2). Prenatal ultrasonography of patient M7 had revealed two tooth germs in the maxilla and none in the mandible, while later on, three teeth were found in the maxilla and none in the mandible (Table 3). In patient F2, however, the number of tooth germs recognized prenatally was clearly reduced (four tooth germs in the maxilla, five in the mandible). Postnatally, eight deciduous and nine permanent teeth were seen in the maxilla as well as 10 deciduous and 12 permanent teeth in the mandible. Sometimes, the germs of permanent teeth could already be detected prenatally: in patient M6, for example, the sonographic tooth germ counts in gestational week 20 exceeded the number of deciduous teeth in both alveolar bones.

In summary, not all fetal tooth germs were detectable in midpregnancy, but all tooth germs identified by ultrasonography in utero corresponded to teeth visible later in a dental radiograph.

Comparison of the results of tooth counting by clinical assessment in preschool children with subsequent radiographic findings showed good agreement (Table 3). In 14 male and five female XLHED subjects aged 4.5 to 5 years, the number of teeth was clearly more diminished in male patients, especially in the mandible. It ranged from two to six deciduous and nil to four permanent teeth in the maxilla and from nil to six deciduous and nil to two permanent teeth in the mandible. The mean number of teeth also differed between mandible and maxilla (4.1 deciduous and 2.1 permanent teeth in the maxilla, 1.5

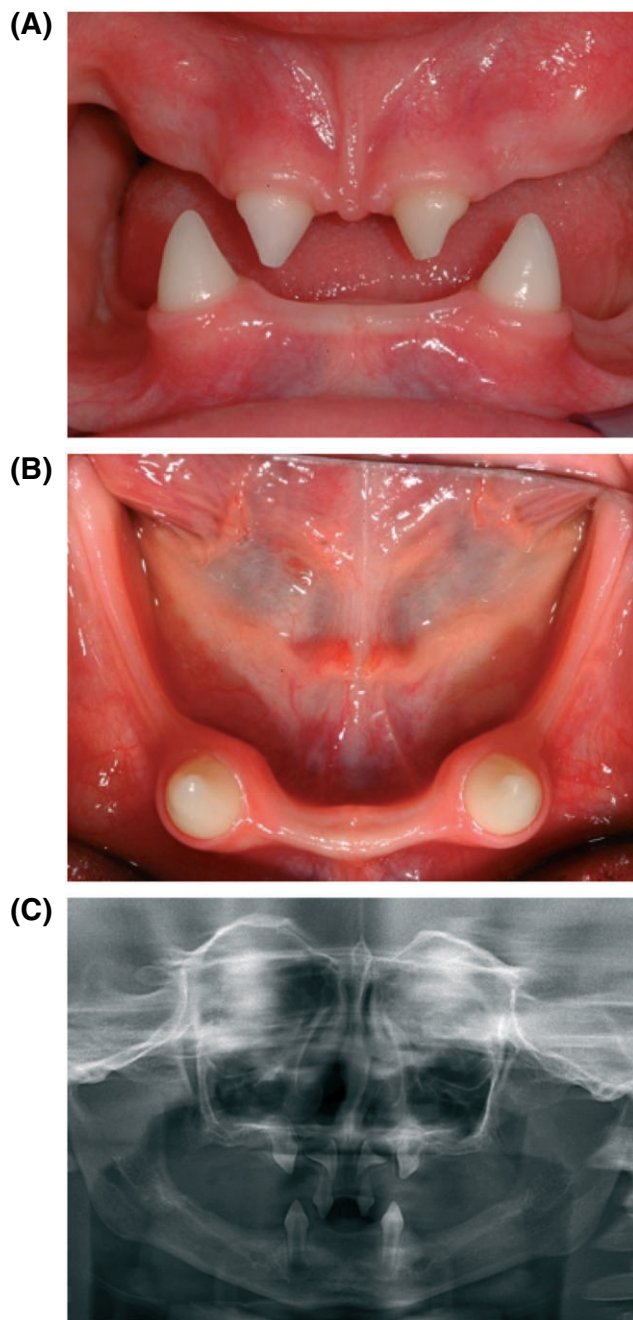


FIGURE 2 Clinical assessment of oligodontia and alveolar hypoplasia. Intraoral dental photographs depicting A, the frontal view and B, the mandible of a boy with X-linked hypohidrotic ectodermal dysplasia (XLHED). The pictures display the typical oligodontia, tooth malformation, and hypoplasia of the edentulous bone regions, which can be diagnosed reliably by palpation. C, Panoramic dental radiograph of the same patient confirming the presence of four teeth as well as two additional upper primary canines and permanent tooth germs for the central incisors [Colour figure can be viewed at wileyonlinelibrary.com]

deciduous and 0.6 permanent teeth in the mandible). Dentition was usually delayed. Many of the teeth had dysmorphic crowns: conical teeth were observed very often. Some teeth were horizontally inclined, especially deciduous teeth without permanent successor (Figures 2 and 3). Taurodontism and taproots (Figure 3) occurred frequently. As observed in the prenatal scans, a reduced number of

teeth/tooth buds were accompanied by obvious alveolar hypoplasia (Figure 2).

Most female subjects with XLHED also had a considerably reduced tooth endowment (mean numbers of 7.8 deciduous and 10.0 permanent teeth in the maxilla and 8.4 deciduous and 11.0 permanent teeth in the mandible). The number of teeth in female subjects, however, showed great interindividual variability (Table 3). Even if it was normal, some of the teeth had morphological abnormalities as observed in male XLHED subjects.

To find out whether the reported weight deficits of boys with XLHED¹³ are acquired prenatally or postnatally, estimated fetal weights and postnatal weight gain were assessed using the weight-for-age charts. The estimated weight of 12 male fetuses with a tooth germ sonography suggestive of XLHED was mostly between the 25th and the 75th percentiles of WHO growth charts for the respective gestational age²⁶; none of the estimated fetal weights fell below the 10th percentile. Thus, the weight of male fetuses with XLHED was not diminished (Figure 4). In the group of 12 male subjects who had already completed the XLHED natural history study, delineation of biometric data in growth charts²⁷ showed that their weight for age was mostly below average. At the age of 5 years, the weight of only two subjects was above the 50th percentile, whereas four of 12 subjects (three of them with very few teeth) had a weight below the 10th percentile (Figure 4). We conclude from these data that weight gain of XLHED subjects is impaired only postnatally.

4 | DISCUSSION

This analysis of 38 cases shows that prenatal tooth germ sonography is a highly reliable method to identify fetuses with XLHED. It was applied to fetuses of pregnant women with known *EDA* mutations, thus in a cohort with a 50% risk of the fetus being affected, however without any false positive result. High specificity and a high positive predictive value are important prerequisites for employing a screening method in a clinical setting where affected subjects may undergo treatment. In accordance with the literature available at the beginning of our study, the number of tooth germs was considered to be reduced if it was below six in at least one alveolar bone.^{22,23} A recent study by Seabra et al²⁰ showed that in many fetuses, 10 tooth germs per alveolar bone can be visualized sonographically; this threshold should, however, not be applied to the prenatal screening for XLHED in a cohort of pregnant women with known *EDA* mutation: the risk of a false positive result would increase and concomitantly the risk of treating an unaffected fetus.

Considering the specificity of 100%, tooth germ sonography would be well suitable for identifying patients to be treated in utero by intraamniotic administration of an *EDA1* replacement molecule, particularly because it does not expose the fetus or the mother to any procedure-related risk. The approach was applicable in different countries at various sites representing different levels of care, in university hospitals as well as in private medical centers. Prenatal screening for oligodontia can easily be integrated into advanced ultrasound examinations to detect fetal anomalies in the first and second trimesters of gestation. Additional equipment is not necessary. However,

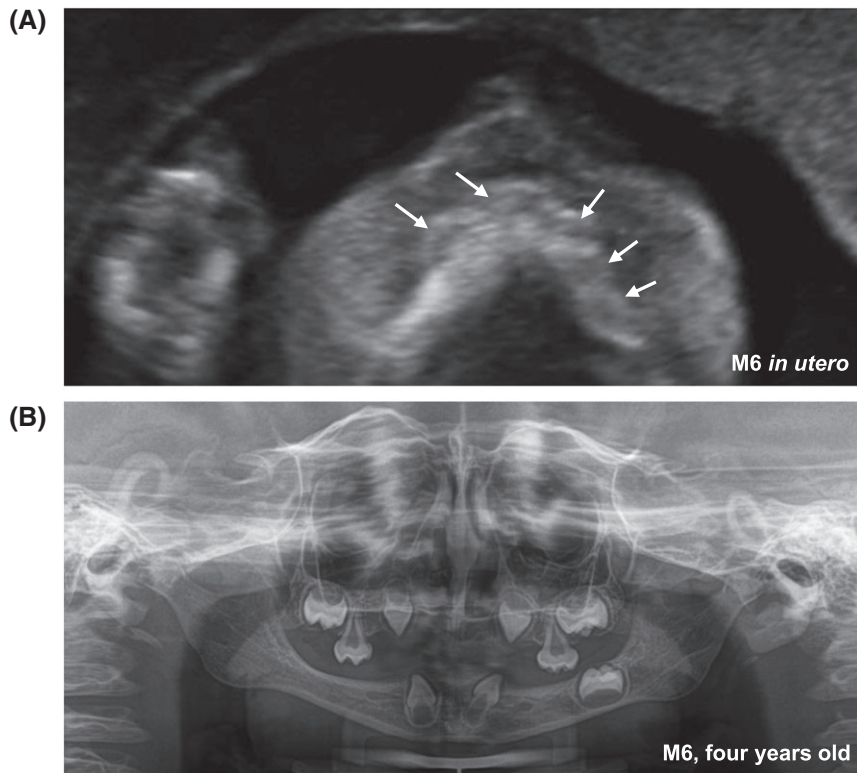


FIGURE 3 Comparison of prenatal tooth germ sonography and corresponding panoramic radiograph. A, A horizontal section of the maxilla of a fetus at 20 weeks of gestation (patient M6) shows only five tooth germs, highlighted by white arrows. On the basis of this finding, X-linked hypohidrotic ectodermal dysplasia (XLHED) was diagnosed. B, Panoramic dental radiograph of the same patient at the age of 4 years

TABLE 3 Number of teeth in 5-year-old subjects with X-linked hypohidrotic ectodermal dysplasia (XLHED) as determined by clinical examination and panoramic dental radiographs

Patient	EDA Mutation	Clinical Assessment:		Number of Teeth, Determined by Dental Radiographs			
		Number of teeth		Maxilla		Mandible	
		Erupted	Tooth buds	Deciduous	Permanent	Deciduous	Permanent
M6	p.R156H	2	7	4	2	2	1
M7	Exon2dupl	2	1	2	1	0	0
M24	p.K359X	2	0	2	0	0	0
M25	c.793G > T ^a	7	4	6	4	1	2
M26	p.G381R	5	5	4	3	2	2
M27	p.D126PfsX10	2	4	4	2	2	0
M28	p.R156QfsX2	1	3	5	0	0	0
M29	p.Y304C	3	1	4	0	0	0
M30	p.R155C	11	5	5	4	6	2
M31	p.R156H	4	0	4	1	0	0
M32	p.P203L	2	3	4	2	1	0
M33	p.Q358X	8	0	4	4	2	2
M34	p.R155C	10	2	6	4	4	0
M35	p.R156H	2	3	4	2	1	0
Mean		4.4	2.7	4.1	2.1	1.5	0.6
F2	p.R156H	18	4	8	9	10	12
F4	p.P220_P225del	15	4	7	8	8	10
F14	p.P191_P196del	20	4	10	12	10	14
F15	p.I371N	8	5	4	7	4	5
F16	p.Q358X	24	4	10	14	10	14
Mean		17.0	4.2	7.8	10.0	8.4	11.0

Abbreviations: EDA, ectodysplasin A; F, female subject; M, male subject.

^aSplice-site mutation.

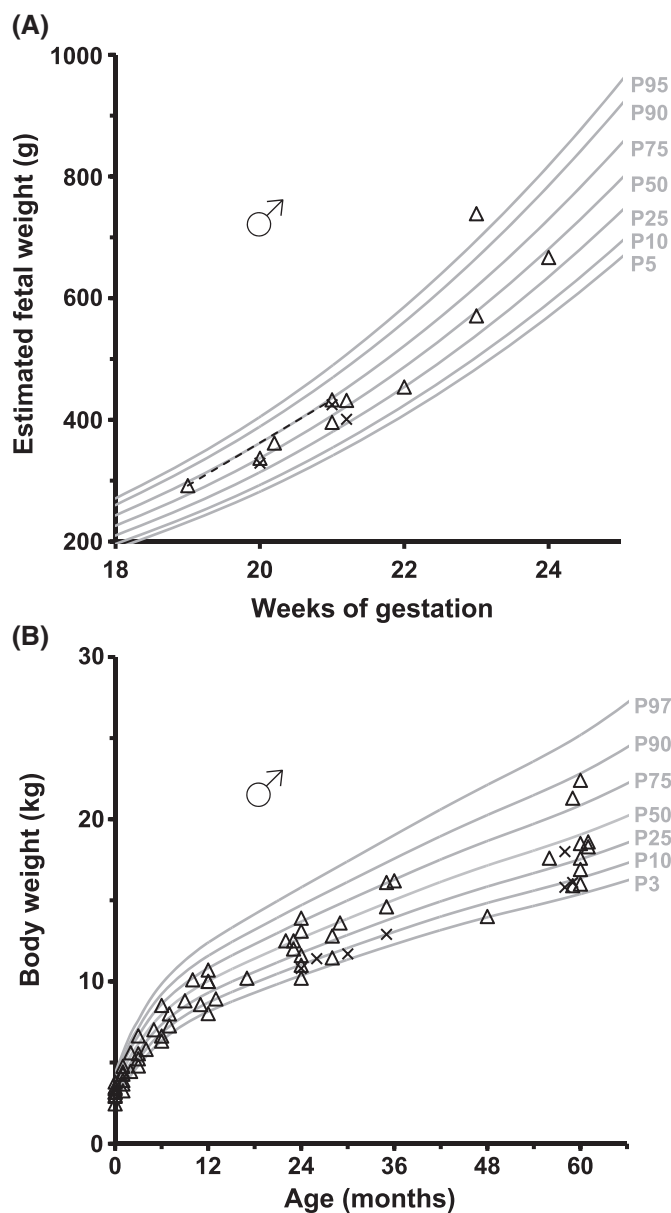


FIGURE 4 Body weight of male subjects with X-linked hypohidrotic ectodermal dysplasia (XLHED). A, The estimated weight of 12 male XLHED fetuses was set in relation to World Health Organization (WHO) fetal growth charts.²⁶ The weight of twins or triplets is indicated as X, the weight of single fetuses as triangle. For one fetus, the weight was estimated at two time points, depicted as triangles connected by a dashed line. None of the fetuses investigated had an estimated weight below the 10th percentile. B, For 12 boys with XLHED, the weight obtained during routine pediatric examinations was delineated in weight-for-age charts.²⁷ The weight of twins or triplets is indicated as X, and the weight of children from a singleton pregnancy is indicated as triangle. In most cases, weight for age was below the 50th percentile. Four of 12 subjects had a weight below the 10th percentile after their 4th birthday

experience and proper training will be required for a correct interpretation of fetal dentition. Thus, tooth germ sonography may be applied broadly to diagnose XLHED early enough for potential treatment.

Apart from this, tooth germ sonography may be offered to all pregnant women with known *EDA* mutation who desire a prenatal diagnosis. Early recognition of XLHED may be crucial for reducing the risk of overheating. Dangerous and sometimes life-threatening episodes of hyperpyrexia occur most often in young infants, because they frequently suffer febrile illnesses and cannot evade overheating by themselves.^{4,10} Beyond infancy, males with XLHED can prevent hyperthermia by avoiding hot and sunny places, by wetting their T-shirt, or by wearing cooling devices during physical activity.^{4,28} Besides genetic testing after diagnostic amniocentesis, measurement of the ratio of variant to normal *EDA* cell-free DNA in the maternal plasma or genotyping of the infant using the cord blood would represent alternative methods to diagnose XLHED either prenatally or perinatally. Measurement of the *EDA* protein in cord blood may be another approach to early recognition of this condition.²⁹

Tooth germ sonography may, however, be applicable more broadly. Prenatal assessment of facial features via two-dimensional ultrasound has become an important part of screening for fetal abnormalities; as oligodontia is associated with fetal pathology in a substantial number of cases, visualization of alveolar structures has been assigned a larger role in prenatal diagnostics.³⁰ Of course, we recognize that under such circumstances—without prior indication of *EDA* gene involvement—the measures of test performance reported here will not apply, since the prior probability that the cause is a pathogenic *EDA* variant will be much smaller.

Numerical or morphological tooth abnormalities were found in all subjects with XLHED investigated postnatally. Oligodontia was more pronounced in the mandible and, as expected, in male subjects. Even if the number of teeth was not considerably reduced in some affected females, their teeth were not all normal. Taurodontism as well as teeth with tapered and conical forms is typical of XLHED.^{11,12} Consistent with previous reports,¹² postnatal tooth quantification showed a wide variability of the number of teeth in females heterozygous for *EDA*

mutations. This phenotypic variability in heterozygous carriers is a characteristic of X-linked diseases and well known in XLHED.⁴ According to the literature, females with XLHED are often diagnosed only because of affected siblings.³¹ In our cohort, however, all four females with XLHED were recognized prenatally, there was no false negative result. This may, in part, be attributed to the small sample size and the genotype of affected female fetuses: three of them carry an *EDA* variant known to be associated with severe oligodontia (two large deletions and a mutation destroying the furin cleavage site of *EDA1*, respectively).³² The sensitivity of tooth germ sonography is probably lower in affected female subjects who do not lack many teeth, and this may represent a potential limitation of the method. The specificity, however, is expected to be high as hypodontia in the female deciduous dentition is rare³³ so that, when it is recognized in a situation of high prior probability of a female carrying a pathogenic *EDA* variant, this makes it very likely that she will indeed be a carrier. Furthermore, the lower sensitivity of the test in female fetuses may be not as invidious as a false positive result in a fetus of either sex.

Genotype-phenotype correlation may also help to explain why one male fetus with XLHED was missed in the prenatal assessments. This subject carries an *EDA* variant, which results in the replacement of a potentially less critical amino acid in the tumor necrosis factor (TNF) homology domain of *EDA1*, and seems to be associated with less severe oligodontia³²; his 5-year-old brother with the same mutation (subject M26) has 11 teeth. Thus, in case of missense mutations known to lead to milder symptoms, tooth germ sonography must be performed with particular attention.

Mandibular hypoplasia is a consequence of oligodontia and was consistently observed prenatally as well as postnatally. Because of missing teeth, reduced alveolar processes, and mandibular hypoplasia, individuals with XLHED often have a typical facial appearance with a negative overjet.^{34,35} Absent or misshaped teeth are frequently the reason to seek medical help for individuals with previously undiagnosed XLHED³⁴ and pose a significant psychosocial burden on the patients.³⁶ Although oligodontia is not life-threatening, it affects the quality of life and may be one of probably multiple causes of impaired postnatal weight gain as observed in our cohort of children with XLHED. Growth abnormalities with a reduced mean weight for age have also been observed by others.¹³ There is no doubt that oligodontia has a negative impact on orofacial functioning and mastication. In addition to salivary gland dysfunction in XLHED,³⁷ this may prevent adequate caloric intake. Therefore, special attention should be paid to timely provision of prostheses.

In summary, oligodontia and mandibular hypoplasia are, at least in affected male subjects, consistent and characteristic features of XLHED that can already be detected prenatally. Tooth germ sonography is a highly reliable method to identify fetuses with XLHED in pregnant women with known *EDA* mutation. This noninvasive method could thus be used regularly to recognize XLHED in time for possible prenatal therapy or prevention of dangerous hyperthermic episodes in early infancy.

ACKNOWLEDGEMENTS

We are grateful to the patients and their families who participated in this study as well as to all members of the medical teams involved.

We thank Dr Jörg Jüngert (Erlangen), Dr Helge Mommsen (Munich), and Dr Katrin Schwanz (Cottbus) for performing tooth germ sonography in individual patients and Dr Alexander Mayr (Erlangen) for statistical advice.

CONFLICT OF INTEREST

None of the authors have any conflicts of interest to declare.

FUNDING INFORMATION

Funding sources: none.

ORCID

Johanna Hammersen  <http://orcid.org/0000-0001-8821-5775>

REFERENCES

- Kere J, Srivastava AK, Montonen O, et al. X-linked anhidrotic (hypohidrotic) ectodermal dysplasia is caused by mutation in a novel transmembrane protein. *Nat Genet.* 1996;13(4):409-416.
- Mikkola ML. Molecular aspects of hypohidrotic ectodermal dysplasia. *Am J Med Genet Part A.* 2009;149:2031-2036.
- Visinoni AF, Lisboa-Costa T, Pagnan NA, Chautard-Freire-Maia EA. Ectodermal dysplasias: clinical and molecular review. *Am J Med Genet Part A.* 2009;149:1980-2002.
- Clarke A, Phillips DI, Brown R, Harper PS. Clinical aspects of X-linked hypohidrotic ectodermal dysplasia. *Arch Dis Child.* 1987;62(10):989-996.
- Itin PH, Fistarol SK. Ectodermal dysplasias. *Am J Med Genet Part C.* 2004;131:45-51.
- Schneider H, Hammersen J, Preisler-Adams S, Huttner K, Rascher W, Bohring A. Sweating ability and genotype in individuals with X-linked hypohidrotic ectodermal dysplasia. *J Med Genet.* 2011;48(6):426-432.
- Dietz J, Kaercher T, Schneider AT, et al. Early respiratory and ocular involvement in X-linked hypohidrotic ectodermal dysplasia. *Eur J Pediatr.* 2013;172(8):1023-1031.
- Fete M, Hermann J, Behrens J, Huttner KM. X-linked hypohidrotic ectodermal dysplasia (XLHED): clinical and diagnostic insights from an international patient registry. *Am J Med Genet Part A.* 2014;164(10):2437-2442.
- Salisbury DM, Stothers JK. Hypohidrotic ectodermal dysplasia and sudden infant death. *Lancet.* 1981;1(8212):153-154.
- Blüschke G, Nüsken KD, Schneider H. Prevalence and prevention of severe complications of hypohidrotic ectodermal dysplasia in infancy. *Early Hum Dev.* 2010;86(7):397-399.
- Präger TM, Finke C, Miethke RR. Dental findings in patients with ectodermal dysplasia. *J Orofac Orthop.* 2006;67(5):347-355.
- Lexner MO, Bardow A, Hertz JM, et al. Anomalies of tooth formation in hypohidrotic ectodermal dysplasia. *Int J Paediatr Dent.* 2007;17(1):10-18.
- Motil KJ, Fete TJ, Fraley JK, et al. Growth characteristics of children with ectodermal dysplasia syndromes. *Pediatrics.* 2005;116(2):e229-e234.
- Gaide O, Schneider P. Permanent correction of an inherited ectodermal dysplasia with recombinant *EDA*. *Nat Med.* 2003;9(5):614-618.
- Casal ML, Lewis JR, Mauldin EA, et al. Significant correction of disease after postnatal administration of recombinant ectodysplasin A in canine X-linked ectodermal dysplasia. *Am J Hum Genet.* 2007;81(5):1050-1056.
- Hermes K, Schneider P, Krieg P, Dang AT, Huttner K, Schneider H. Prenatal therapy in developmental disorders: drug targeting via intra-amniotic injection to treat X-linked hypohidrotic ectodermal dysplasia. *J Invest Dermatol.* 2014;134(12):2985-2987.

17. Huttner K. Future developments in XLHED treatment approaches. *Am J Med Genet Part A*. 2014;164(10):2433-2436.
18. Schneider H, Faschingbauer F, Schuepbach-Mallepell S, et al. Prenatal correction of X-linked hypohidrotic ectodermal dysplasia. *New Engl J Med*. 2018;378(17):1604-1610.
19. Ulm MR, Chalubinski K, Ulm C, Plöckinger B, Deutinger J, Bernaschek G. Sonographic depiction of fetal tooth germs. *Prenat Diagn*. 1995;15(4):368-372.
20. Seabra M, Vaz P, Valente F, Braga A, Felino A. Two-dimensional identification of fetal tooth germs. *Cleft Palate Craniofac J*. 2017;54(2):166-169.
21. Sepulveda W, Sandoval R, Carstens E, Gutierrez J, Vasquez P. Hypohidrotic ectodermal dysplasia: prenatal diagnosis by three-dimensional ultrasonography. *J Ultrasound Med*. 2003;22(7):731-735.
22. Wünsche S, Jüngert J, Faschingbauer F, et al. Noninvasive prenatal diagnosis of hypohidrotic ectodermal dysplasia by tooth germ sonography. *Ultraschall Med*. 2015;36(4):381-385.
23. Ulm MR, Kratochwil A, Ulm B, Solar P, Aro G, Bernaschek G. Three-dimensional ultrasound evaluation of fetal tooth germs. *Ultrasound Obstet Gynecol*. 1998;12(4):240-243.
24. Clopper C, Pearson ES. The use of confidence or fiducial limits illustrated in the case of the binomial. *Biometrika*. 1934;26(4):404-413.
25. Hadlock FP, Harrist RB, Carpenter RJ, Deter RL, Park SK. Sonographic estimation of fetal weight. The value of femur length in addition to head and abdomen measurements. *Radiology*. 1984;150(2):535-540.
26. Kiserud T, Piaggio G, Carroli G, et al. The World Health Organization fetal growth charts: a multinational longitudinal study of ultrasound biometric measurements and estimated fetal weight. *PLoS Med*. 2017;14(1):e1002220.
27. Neuhauser H, Schienkiewitz A, Schaffrath Rosario A et al. Referenzperzentile für anthropometrische Maßzahlen und Blutdruck aus der Studie zur Gesundheit von Kindern und Jugendlichen in Deutschland (KiGGS). Beiträge zur Gesundheitsberichterstattung des Bundes. 2nd edition. Robert Koch-Institut, Berlin, 2013;22-31.
28. Hammersen JE, Neukam V, Nüsken KD, Schneider H. Systematic evaluation of exertional hyperthermia in children and adolescents with hypohidrotic ectodermal dysplasia: an observational study. *Pediatr Res*. 2011;70(3):297-301.
29. Podzus J, Kowalczyk-Quintas C, Schuepbach-Mallepell S, et al. Ectodysplasin A in biological fluids and diagnosis of ectodermal dysplasia. *J Dent Res*. 2017;96(2):217-224.
30. Seabra M, Felino A, Nogueira R, Valente F, Braga AC, Vaz P. Prenatal ultrasound and postmortem histologic evaluation of tooth germs: an observational, transversal study. *Head Face Med*. 2015;11(1):18.
31. Nguyen-Nielsen M, Skovbo S, Svaneby D, Pedersen L, Fryzek J. The prevalence of X-linked hypohidrotic ectodermal dysplasia (XLHED) in Denmark, 1995-2010. *Eur J Med Genet*. 2013;56(5):236-242.
32. Zeng B, Lu H, Xiao X, et al. Novel EDA mutation in X-linked hypohidrotic ectodermal dysplasia and genotype-phenotype correlation. *Oral Dis*. 2015;21(8):994-1000.
33. Brook AH. Dental anomalies of number, form and size: their prevalence in British schoolchildren. *J Int Assoc Dent Child*. 1974;5(2):37-53.
34. Bergendal B. Orofacial manifestations in ectodermal dysplasia—a review. *Am J Med Genet Part A*. 2014;164(10):2465-2471.
35. Hadj-Rabia S, Schneider H, Navarro E, et al. Automatic recognition of the XLHED phenotype from facial images. *Am J Med Genet Part A*. 2017;173(9):2408-2414.
36. Saltnes SS, Jensen JL, Sæves R, Nordgarden H, Geirdal AØ. Associations between ectodermal dysplasia, psychological distress and quality of life in a group of adults with oligodontia. *Acta Odontol Scand*. 2017;75(8):564-572.
37. Lexner MO, Bardow A, Hertz JM, et al. Whole saliva in X-linked hypohidrotic ectodermal dysplasia. *Int J Paediatr Dent*. 2007;17(3):155-162.

How to cite this article: Hammersen J, Wohlfart S, Goecke TW, et al. Reliability of prenatal detection of X-linked hypohidrotic ectodermal dysplasia by tooth germ sonography. *Prenatal Diagnosis*. 2019;39:796-805. <https://doi.org/10.1002/pd.5384>